

# Gall bladder carcinoma: Computed Tomographic findings in 50 cases.

Dr Ashok K Mandal<sup>[1]</sup>, Dr Sithanthaseelan M<sup>[2]</sup> & Dr Vinita Thakur<sup>[3]</sup>

<sup>1</sup>Professor, Dept of Radiology, Patna Medical hospital, India

<sup>2,3</sup>Post Graduate Resident, Dept. of Radiology, Patna Medical hospital, India.

## ABSTRACT

**Background:** Gall bladder carcinoma (GBC) is diagnosed late and is twice as common among women in the gangetic belt of north India. GBC are most commonly associated with cholelithiasis. Mortality rate is very high with 5 year survival rate at 5%.

**Aim and method:** Here we assess retrospectively with computed tomography (CECT) scan imaging findings in histopathologically proven cases of GBC to review the most relevant findings associated with gallbladder cancer. This study included 50 patients presented to us during the period from November 2016 till May 2017 and underwent ultrasonography followed by computed tomographic imaging using contrast and triphasic CECT.

**Result:** 28 patients had an infiltrating mass infiltrating into the liver or adjacent bowel. 16 patients presented with focal or diffuse intraluminal mass and mural thickening of the gall bladder was detected in 6 patients.

**Conclusion:** CECT is the diagnostic modality of choice for detecting, evaluating and characterizing the lesion.

**Key Words :** Gall bladder carcinoma, gangetic belt, infiltrating mass, cholelithiasis, computed tomography (CECT).

## 1. Introduction

The fifth commonest gastrointestinal tract malignancy in the world is GBC and the commonest biliary tree malignancy<sup>[1]</sup>. Common risk factors for GBC are gallstones (65–95%) and a history of chronic cholecystitis (40–50%), repetitive infection, salmonella typhii carrier state and genetic predisposition<sup>[2]</sup>. Gallbladder carcinoma has a peak incidence in the sixth and seventh decades of life and is three to five times more predominant in females<sup>[3]</sup>. Gallbladder carcinoma may appear as a mass completely occupying or replacing the lumen, focal or diffuse asymmetric gallbladder wall thickening, or an intraluminal polypoidal lesion<sup>[3]</sup>.

Modern imaging has made great strides in the diagnosis of GBC but despite the widespread use of imaging techniques, early diagnosis is rare because there are no specific signs and symptoms and many Gallbladder carcinomas are not diagnosed preoperatively. The ease by which this tumor invades the liver and surrounding structures including the biliary tree contributes to its high mortality. The median survival is 6 months, indicating that the majority of patients present with advanced disease. At the time of diagnosis, most patients are considered unresectable because of direct aggressive extension into adjacent organs or distant metastatic disease. However Tumors confined to the gall bladder or with limited infiltration of the adjacent liver segments are considered resectable and managed surgically by cholecystectomy and liver segmentectomy<sup>[4]</sup>.

Abdominal ultrasound in patients of carcinoma GB is the first and most common imaging modality employed though it has various limitations. CT overcomes most limitations and provides definite information regarding invasion into the adjacent organs, distant metastasis, biliary tree and portal vein involvement. Magnetic Resonance Imaging (MRI) is utilized in inoperable cases for delineation of the biliary tract anatomy in patients considered for palliative stenting<sup>5</sup>. We present our CT imaging findings in 50 histologically proven cases of GBC.

## 2. Subjects and methods

This study included fifty patients presented to us during the period from November 2016 till May 2017 of which 35 were females and 15 males. The patients were histopathologically proven cases of carcinoma GB who presented in Patna Medical College and Hospital, Patna. The youngest was 41 and the oldest 65 years in age. The 50 cases were selected from a number of suspected GBC detected in ultrasound were followed up post op and confirmed with HPE and their CT appearance was analyzed and reviewed. Ethical clearance and informed consent as required were obtained at the time of study from the patients. All the patients were subjected to ultrasonography followed by CT

scan imaging using GE High Speed Computed Tomography scanner. The CT scan technique employed in our patients included a preliminary non contrast scan of the abdomen followed by contrast enhanced scans with intravenous injection of non-ionic iodinated contrast medium after orally administered iodinated contrast for opacification of bowel. Scanning was performed during the arterial and portal venous phases and delayed scans done after 4 min.

### 3. Statistical analysis

Microsoft office 2007 was used for analyzing and cataloguing of collected data.

### 4. Results

Among the fifty patients included in this study there was female preponderance in the ratio of 7 females for three males. All the patients (100%) presented with abdominal pain not responding to conservative treatment. Fifteen patients presented with a clinically palpable lump (30%) and obstructive jaundice was the presentation in 20 patients (40%). The main patterns on imaging were an infiltrating mass infiltrating into the liver or adjacent bowel in 28 patients, 16 patients presented with focal or diffuse intraluminal mass and 6 patients had mural thickening of the gall bladder wall. Gall bladder stones were detected in 18 patients (36%). Intrahepatic biliary radicals were dilated in 30 patients (60%) ranging from minimal to severe bilobar dilation. Chronic cholecystitis were detected in 8 patients (16%) perforation of the GB was seen in 2 patients (4%). Adjacent lymph nodes were involved in 30 patients. Of which 20 involved the porta hepatis and celiac nodes and 10 involving the retroperitoneal nodes, the rest involved both with necrotic changes. AJCC TNM system was used to classify the lesions. In the TNM system, T1 tumours involve only the mucosa and muscle layer, T2 tumours involve the peri-muscular connective tissue and has not spread outside the GB, T3 tumours extend beyond the serosa but involve less than 2 cm of the liver and T4 tumours invade beyond 2 cm of the liver. N1 denotes nodes in the cystic duct and portal groups while N2 indicates involvement of retro-pancreatic, aorto-caval and superior mesenteric lymph node groups. The TNM system was used to stage the disease with stage I and II representing T1 and T2 tumours without nodal or distant metastases, T3 and/or N1 disease as stage III, T4 tumours with N1/N0 were included in stage IVA whereas T4 tumours with distant nodal involvement or metastases (N2; M1) were considered as stage IVB. The study findings are tabulated in Table 4. It was seen that patients having an imaging morphology of GB mass

occupying the GB fossa formed the bulk of the cases, with disease stage at diagnosis being Stage IV in 29 (58%) patients.

Early stages show only focal or diffuse wall thickening, intermediate stage is of a focal mass within the lumen and in advanced stage there is a large mass replacing the entire gallbladder. All cases were histopathologically diagnosed to be adenocarcinoma.

### 5. Discussion

Gall bladder adenocarcinomas present in one of three morphologies<sup>[2][3]</sup>:

1. intraluminal mass
2. diffuse mural thickening
3. mass replacing the gallbladder

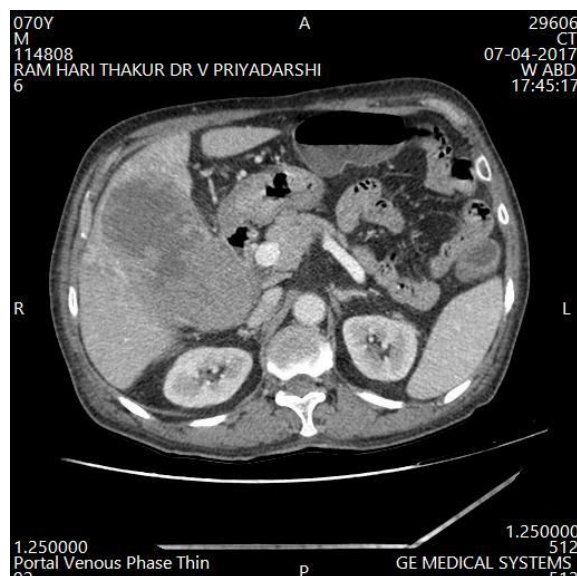
This study included 50 patients presented to us during the period from November 2016 to May 2017 and were diagnosed radiologically by computed tomography as GBC and the diagnosis was confirmed histopathologically.

According to a study of patients with gallbladder cancer the majority of gallbladder carcinomas are diffusely infiltrating lesions, whereas the remaining gallbladder carcinomas exhibit intraluminal mass<sup>6</sup>. It is difficult to diagnose cases of early stage of GBC because the presentation of early GBC is wall thickening which is more commonly found in acute and chronic inflammatory conditions of the gallbladder. The vague nature of symptoms and the non specific nature of early findings causes patients to be diagnosed late when the lesion has infiltrated into the adjacent liver which is due to the anatomical characteristic of the GB wall having a narrow lamina propria and only a single muscle layer<sup>[5]</sup>. If the lesion has infiltrated into the adjacent liver segments 4 and 5 it is still considered resectable with adequate segmentectomy of the involved liver or bowel.

**Table 1. Tabulating the distribution of findings**

Imaging findings	NO of	T	N	M	Stage
	Cases	T1	T2	T3	T4
Wall thickening	6	2	4		
Intraluminal mass	16	4	10	2	
Infiltrating mass	28			20	8
Total	50	6	14	22	8

Around 28 patients had an infiltrating mass on CT which accounted for 56 % of the cases studied. Most of the lesions were seen invading segment 5 in 14 cases and segment 4 in 5 cases, the rest of the cases had invasion into both segments obscuring the anatomy of the organ. Grand et al. stated that contrast material enhanced CT in such cases may demonstrate a hypoattenuating or isoattenuating mass in the gallbladder fossa and soft-tissue invasion of the liver<sup>[8]</sup>. Since triphasic CT was done we were able to rule out other malignant lesions such as hepatocellular carcinoma which show early filling in arterial phase with washout of contrast in delayed and venous phase with a normal GB albeit compressed or displaced if at all by the hepatic primary. The common characteristic pattern of enhancement seen in the study cases was a hypodense lesion as compared to normal liver parenchyma on NCCT showing mild to moderate heterogenous enhancement in post contrast images which was marked in pay contrast phase.



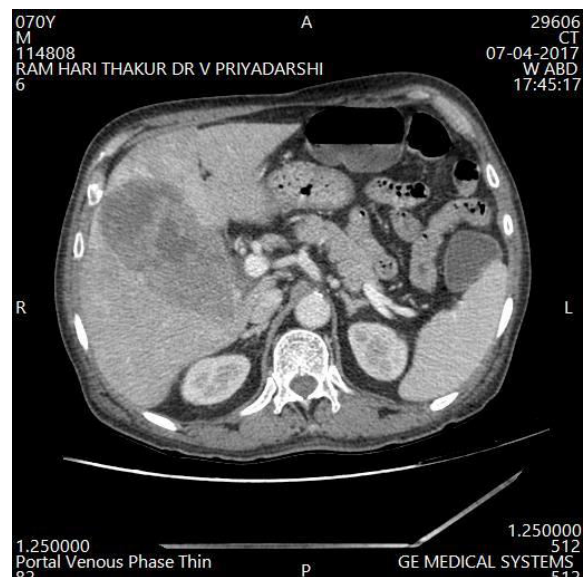
**Figure 1. A large infiltrating mass replacing GB**

Some of the lesions showed predominantly central low attenuation areas suggestive of necrosis. In this study in all of the fifteen patients presenting with such a pattern of gall bladder carcinoma the masses were initially hypodense to the liver tissue out of which nine had mild to moderate heterogeneous contrast enhancement in the portal venous phase of contrast enhancement while six showed no significant enhancement in either phase of contrast enhancement. Xantho-granulomatous cholecystitis may mimic the above appearances of a mass in the GB fossa with spread of inflammation into liver, duodenum and colon.<sup>[9]</sup>

The presence of intramural hypoattenuated nodules occupying a large area of the thickened GB wall is

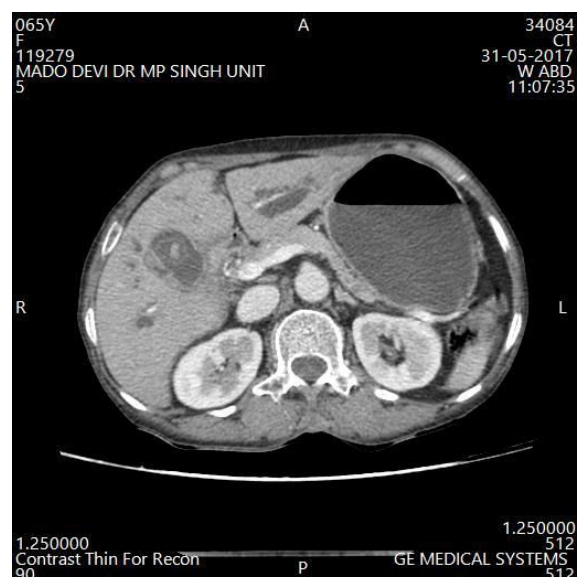
considered diagnostic of xantho-granulomatous cholecystitis<sup>[9]</sup>.

Intraluminal polypoidal masses were detected in 16 patients (32%). The polyps showed mild to moderate enhancement following intravenous contrast administration. Other differential diagnosis of an intraluminal masses are clot, stone and sludge should be excluded. The lesion were diagnosed as an intraluminal mass because of soft tissue attenuation and enhancement of the mass, suggesting the neoplastic nature of these lesions and all of them were confirmed histopathologically following cholecystectomy.



**Figure 2. Same patient showing the adjacent liver invasion.**

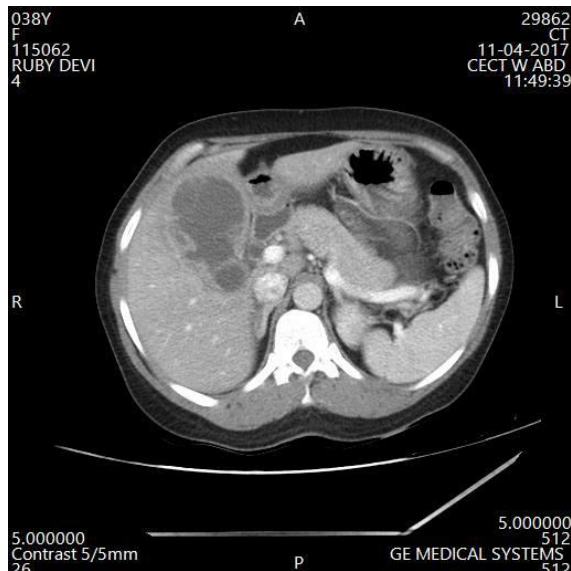
These lesions did not show central areas of necrosis or calcifications.



**Figure 3. Focal wall thickening with cholelithiasis.**

Wall thickening focal or diffuse is difficult to be diagnosed as GBC since GB wall thickening is seen in wide range of clinical settings such as chronic cholecystitis, adenomyomatosis, inadequate GB distension, hepatitis and low protein states<sup>[8]</sup>. 6 patients (12%) had focal or diffuse wall thickening in our study. Soo et al. presented that wall thickening of the gall bladder showed two patterns of enhancement that were significant predictors of malignancy<sup>[10]</sup>

1. Two-layered wall thickening showing a strongly enhancing thick inner mucosal layer and a weakly enhancing or non-enhancing outer layer
2. One-layer of wall thickening showing heterogeneous enhancement.



**Figure 4 Focal eccentric wall thickening**

A thin enhancing inner layer with a thick non enhancing outer layer denoting subserous edema was suggestive of acute cholecystitis. A hypodense halo representing mural oedema in the thickened GB wall has been described as a sign of cholecystitis rather than carcinoma<sup>[11]</sup>. A thin mildly enhancing inner layer and a non enhancing thin outer layer was characteristic of chronic cholecystitis. The presence of two enhancement-layer patterns with low attenuated foci within the inner layer suggesting dilated Rokitsky-Aschoff sinuses indicates the presence of adenomyomatosis<sup>[12]</sup>.

In the present study, lymph nodes around the celiac axis and porta hepatis (N1 stage) were involved in 20 out of 30 patients, whereas retroperitoneal nodal involvement (N2 stage) was seen in the remaining patients. Metastatic lesions were detected by CT as Enlarged metastatic abdominal lymph nodes in 30 patients (60%), metastatic hepatic deposits were

detected in 20 patients (40%), metastatic pulmonary nodules were detected in 5 patients (10%), local invasion of adjacent bowel loops was seen in 5 (10%)

Finally we conclude that CE-CT is the diagnostic tool of choice in the detection and staging of gall bladder carcinoma, Yoshimitsu et al, reported an accuracy of 83-86% in diagnosing the local extent of carcinoma GB, but reported poor sensitivity for T1 lesions<sup>[13]</sup>. Kim et al<sup>[14]</sup>, have reported an overall accuracy of 71% in staging the T-factor of the TNM staging in their study of 100 consecutive cases, with accuracies varying from 79% for T1 & T2, 46% for T3 and 73% for T4. The accuracy was lowest for thickened GB wall at 54% and highest for GB mass at 89%. Kumaran et al, in their study have reported 93.3% accuracy in predicting non-resectability using a set criteria<sup>[15]</sup>. The criteria applied were patients with distant metastases (liver, peritoneum, distant lymph nodes), extensive contiguous local organ spread (duodenum, pancreas, colon), involvement of the secondary biliary confluence and tumoral invasion of the main portal vein or proper hepatic artery or simultaneous invasion of one side hepatic artery and other side portal vein. So computed tomography plays a major role in categorizing the lesions according to the staging criteria and its patterns of spread which are essential for planning of the treatment.

## Conclusion

Our study has shown that infiltrating mass lesion to be the commonest presentation of GBC in our setting with a striking gender predisposition. CECT is highly sensitive in diagnosing GBC lesions especially contrast studies to pick up T3 lesions with ease. To diagnose T1 and T2 lesions is a challenge and requires a trained eye to differentiate from other benign causes of similar presentations.

Further studies are needed to identify the reason for gender predilection and determinant factors predisposing the local population to GBC and the reason for the late presentation and diagnosis.

## References

1. Lazcano-Ponce EC, Miquel JF, Muñoz N, et al. Epidemiology and molecular pathology of gallbladder cancer. *CA: Cancer J Clin* 2001. 2001;51(6):349–364.
2. A.D. Levy, L.A. Murakata, C.A. Rohrmann Jr. Gallbladder carcinoma: radiologic–pathologic correlation. *Radiographics*, 21 (2001), pp. 295–314

3. Abhishek Vijayakumar, Avinash Vijayakumar, Vijayraj Patil, M. N. Mallikarjuna, and B. S. Shivaswamy, "Early Diagnosis of Gallbladder Carcinoma: An Algorithm Approach," *ISRN Radiology*, vol. 2013, Article ID 239424, 6 pages, 2013. doi:10.5402/2013/239424.
4. S.E. Jung, J.M. Lee, K. Lee, *et al.* Gallbladder wall thickening: MR imaging and pathologic correlation with emphasis on layered pattern
5. Fong Y, Kemeny N, Lawrence TS. Cancer of the Liver and Biliary tree. In: DeVita VT Jr, Hellman S, Rosenberg SA, editors. *Cancer : Principles and Practice of Oncology*. 6th ed. Philadelphia: Lippincott, Williams and Wilkins, 2002; 1187-202.
6. H.U. Sons, F. Borchard, B.S. Joel Carcinoma of the gallbladder: autopsy findings in 287 cases and review of the literature *J Surg Oncol*, 28 (1985), pp. 199–206
7. *Grulich AE, Mcardie M, Coates M.* Cancer incidence in Asian migrants to New South Wales Australia. *Br J Cancer* 1995;71:400-408.
8. D. Grand, K.M. Horton, E.K. Fishman CT of the gallbladder: spectrum of disease *AJR*, 183 (2004), pp. 163–170
9. Chun KA, Ha HK, Yu ES, Shinn KS. Xantho-granulomatous cholecystitis : CT features with emphasis on differentiation from gallbladder carcinoma. *Radiology* 1997; 203 : 93-7.
10. Soo Jin Kim, Jeong Min Lee, Jae Young Lee, *et al.* Analysis of enhancement pattern of flat gallbladder wall thickening on MDCT to differentiate gallbladder cancer from cholecystitis
11. Haaga JR, Herbener EH. The gallbladder and biliary tract. In: Haaga JR, Lanzieri CF, Gilkeson RC, editors. *CT and MR Imaging of the whole body*. 4th ed. St Louis: Mosby, 2003; 1357-60.
12. E.J. Yun, S.G. Cho, S. Park, *et al.* Gallbladder carcinoma and chronic cholecystitis: differentiation with two-phase spiral CT *Abdominal Imaging*, 29 (2004), pp. 102–108
13. Yoshimitsu K, Honda H, Shinoraki K, Aibe H. Helical CT of the local spread of carcinoma of the gallbladder: evaluation according to the TNM system in patients who underwent surgical resection. *Amer J Roentgen* 2002; 179: 423-8
14. Kim BS, Ha HK, Lee IJ, Kim JH. Accuracy of CT in staging of Gallbladder carcinoma. *Acta Radiol* 2002; 43 : 25.
15. Kumaran V, Gulati S, Paul B, Pande K. The role of dual phase helical CT in assessing resectability of carcinoma of the gallbladder. *Europ Radiol* 2002; 12: 1993-9.
16. Kapoor VK, McMichael AJ. Gallbladder cancer: An 'Indian' disease. *The Nat Med Jour India*. 2003;16:209–213.
17. National Cancer Registry Program Report. [http://www.icmr.nic.in/ncrp/PBCR\\_Report %202009\\_2011](http://www.icmr.nic.in/ncrp/PBCR_Report%202009_2011). Accessed on 22 April 2015.