

# Multidisciplinary Approach to the Rehabilitation of a Tooth with a Complicated Crown-Root Fracture: A Case Report

S. Datta Prasad<sup>1</sup>, O.Pavankumar<sup>2</sup>, K. Sasidhar Reddy<sup>3</sup>

<sup>1</sup>Professor and Head, Department of Conservative Dentistry and Endodontics, C.K.S.Theja Institute of Dental Sciences, Tirupati, Andhra Pradesh, India.

<sup>2</sup>Post Graduate Student, Department of Conservative Dentistry and Endodontics, C.K.S.Theja Institute of Dental Sciences, Tirupati, AP, India. dr.pavanendo@gmail.com

<sup>3</sup>Professor Department of Conservative Dentistry and Endodontics, C.K.S.Theja Institute of Dental Sciences, Tirupati, AP, India.

---

**Abstract:** Coronal tooth fractures are most common in anterior teeth, especially in maxillary teeth due to their anatomical position. They create serious esthetic and psychological problems for the patient. Esthetical rehabilitation of fractured anterior teeth is one of the greatest challenges to a dentist. This case report describes the clinical procedures involved in the management of a complicated crown-root fracture of mandibular right canine. Complicated crown fracture and crown-root fracture pose difficulties for dentists to establish adequate treatment plans because these fractures require multidisciplinary approach for proper treatment planning and good prognosis. Clinical and radiographic examination revealed a complicated crown-root fracture of mandibular right canine. Post trauma treatment comprised of single visit root canal therapy followed by crown lengthening with laser and osteoplasty was performed. After one week, the tooth was restored with post-core system and finally a prosthetic crown. A tooth that would have been extracted routinely was thus saved and restored through the use of a collaborative approach.

**Key Words:** Crown-root fracture, Traumatic dental injuries, Permanent tooth, Case report

## Introduction:

Fracture of a tooth below the gingival attachment or crest of the alveolar bone presents an extremely complicated restorative problem. A crown-root fracture is a type of dental trauma, generally consequential from horizontal impact, which involves enamel, dentin and cementum, occurs below the gingival margin and may be classified as complicated or uncomplicated, depending on whether pulp involvement is present or absent [1]. Epidemiological statistics revealed that crown-root fractures correspond to 5% of dental injuries

[2]. Treatment of complicated crown-root fractures is often challenging due to difficulty in achieving isolation with a rubber dam for a dry operating field. The lag time esthetic requirement determines the treatment strategy. Three different treatment options should be discussed [3]:

1. The fractured portion can be used either as a temporary crown or permanent crown
2. Orthodontic or surgical extrusion or a crown lengthening and then followed by a definitive crown
3. An immediate or delayed implant surgery after extraction of the residual tooth

These fractures are usually caused by direct trauma in anterior teeth and are often complicated. The treatment modalities can be changed depending on the level of fracture line and the amount of remaining root. If the fracture involves maximum the coronal third of the root and the remaining root structure is sufficient to support the subsequently applied restoration, only the fractured portion is extracted and root canal therapy is performed [4]. In the later case, gingivectomy, surgical or orthodontic extrusion of the apical fragment is essential to convert the subgingival fracture into a supragingival one.

## Case report:

A 28 year old male reported to the Department of Conservative dentistry & Endodontic with a chief complaint of injured right lower anterior teeth due to a bike accident happened a day earlier. His medical and dental histories were unremarkable. Clinical examination showed lacerations of the lower lip with moderate edema. On intra oral examination a bleeding line was noticed in the cervical region of mandibular right canine (see

Figure 1a). When the tooth was gently probed, the tooth fragment was extremely mobile as it was only retained by periodontal fibers on the lingual aspect. Radiographic examination clearly revealed a transverse complicated crown root fracture at the cervical region (see Figure 1b). The root of the mandibular right canine was fully developed and did not show any periapical pathosis. After performing local anesthesia, the transversely fractured crown root portion was separated from the remaining tooth by means of forceps (see Figure 1c). After cleaning and shaping the root canal was obturated by using lateral condensation technique (see Figure 2a). Since the crown fragment has many micro fractures it was not advisable for reattachment procedure. Clinical crown lengthening procedure was done using laser (Diode) assisted gingivectomy (see Figure 2b). The guttapercha was partially removed leaving the apical 5mm of the filling to maintain a good seal and the prefabricated fiber post was placed followed by a composite core build up (see Figure 2c). An Apically positioned flap (APF) with osseous reduction was performed since the labial gingiva was inflamed (see Figure 3a). The flap was positioned apically using vertical mattress sutures and periodontal dressing was placed. After 1 week of clinical crown lengthening surgery (see Figure 3b), crown preparation was done for all ceramic restoration. Final impressions were made with two stage impression technique using putty and light body elastomeric impression material. A temporary crown was cemented on the same appointment. The finished final restoration was cemented with glass ionomer luting cement after three days (see Figure 4a). Follow up was done after 24 weeks (see Figure 4b) with no evidence of any periapical pathosis and the treated tooth was satisfactory both esthetically and functionally.

#### Discussion:

The alternative treatment modalities of crown root fractures are fragment reattachment, orthodontic extrusion or surgical extrusion, crown lengthening procedures. Bonding the coronal fragment to the root structure can be a permanent treatment in some cases, but in the present case the subgingival location of the fracture line along with the micro fractures could not allow an optimal sealing [3]. Orthodontic extrusion is more time consuming procedure which requires an activation period of four to six weeks and six to eight weeks of retention period for the tooth to become stabilized in its new position and also a costly treatment. Since the patient in this case could not afford much time this procedure was not opted [5]. Surgical extrusion could be more traumatizing along with

risk of external resorptions [6]. Clinical crown lengthening is a periodontal restorative procedure, it has been categorized as aesthetic or functional. It involves various techniques, including gingivectomy, apically positioned flap procedure, which may include osseous resection [7]. Gingivectomy is a simple and rapid method and allows the restorations to be completed soon after the injury [8]. It is often necessary to remove the supporting bone from around a tooth to achieve adequate distance between the alveolar crest and the margins of the restoration [4]. In the present case with a complicated crown root fracture with pulp exposure the techniques for reestablishment of the biological width have been proposed followed by a restorative treatment indicated according to the remaining dental structure. The cementation of aesthetic posts in the root canal permits the construction of direct cores which facilitates tooth restoration. This report provides a highly conservative approach that combines esthetics, function and health of the periodontal tissues.

#### Conclusion:

Complicated and uncomplicated crown root fractures posed the greatest difficulties for the dentist to establish adequate treatment plans. The present case shows the multidisciplinary management of dental trauma leading to the conservation of the tooth and its permanent restoration.

#### References:

- [1] Andreasen JO, Andreasen FM. *Textbook and color atlas of traumatic injuries to the teeth*. 4<sup>th</sup> ed. Oxford: Blackwell; 2007.
- [2] Sandra Rivera, Rivail Antonio Sergio, Luciana Moura SASSONE, Cristiana Francescutti MURAD. *Clinical Management of a Complicated Crown-Root Fracture: A Case Report*. *Braz Dent J* (2011) 22(3): 258-262.
- [3] Villat C, Machtou P, Naulin-Ifi C. *Multidisciplinary approach to the immediate esthetic repair and long-term treatment of an oblique crown-root fracture*. *Dent Traumatol* 2004; 20:56-60.
- [4] Arvind Shenoy, Nina Shenoy, Roopa Babannavar. *Periodontal considerations determining the design and location of margins in restorative dentistry*. Year : 2012 | Volume : 2 | Issue : 1 | Page : 3-10
- [5] Zhengyan Wang, Michelle Heffernan, William F Vann Jr. *Management of a complicated crown-root fracture in a young permanent incisor using intentional replantation*. *Dental Traumatology* 2008; 24: 100-103;
- [6] Olsburgh S, Jacoby T, Krejci I. *Crown fractures in the permanent dentition: pulp and restorative considerations*. *Dent Traumatol* 2002; 18:103-115.

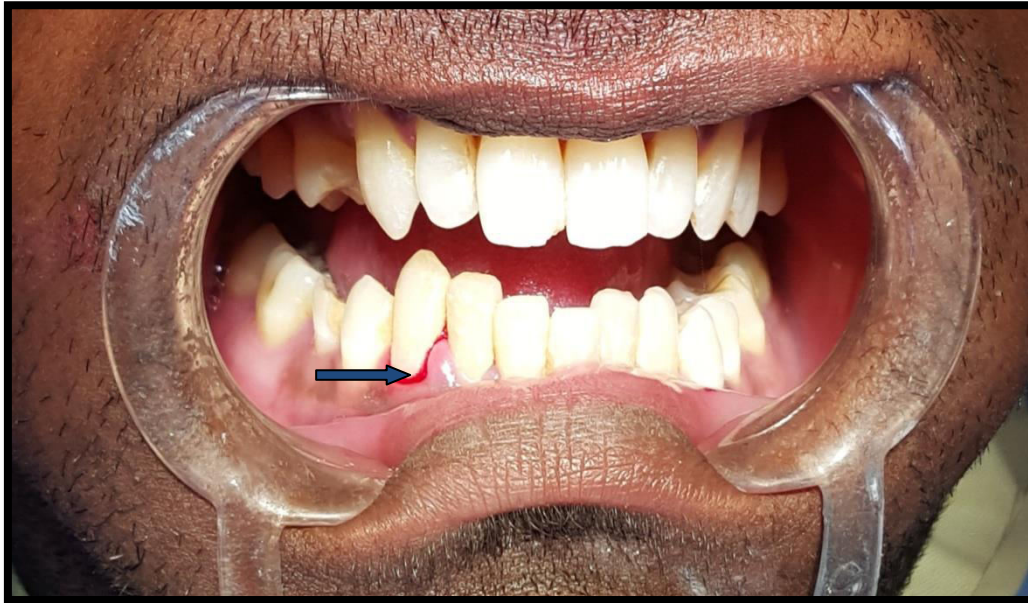[7]S Milavec<sup>1</sup> and B Gaspirc<sup>2</sup> <sup>1</sup>Zdravstveni dom Sežana, Partizanska, Sežana. *CASE REPORT: Clinical Crown Lengthening: Laser-Assisted Versus Conventional surgical therapy. Journal of the Laser and Health Academy Vol. 2014, No.1;*

[8]Turgut MD, Go`nu` l N, Altay N. *Multiple complicated crown–root fracture of a permanent incisor. Dent Traumatol 2004; 20: 288–292.*

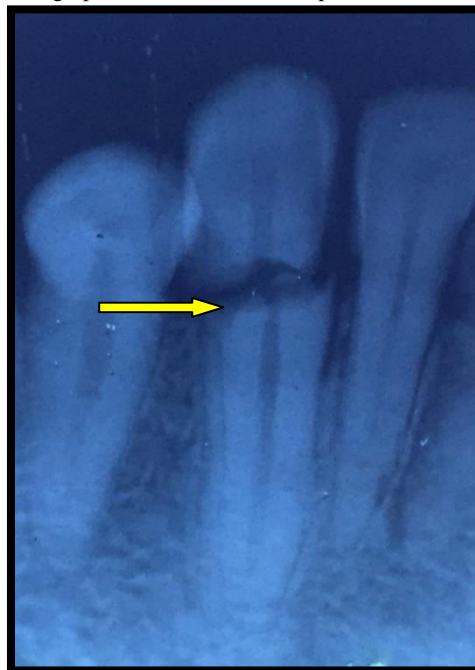**Figures**

**Figure 1:**

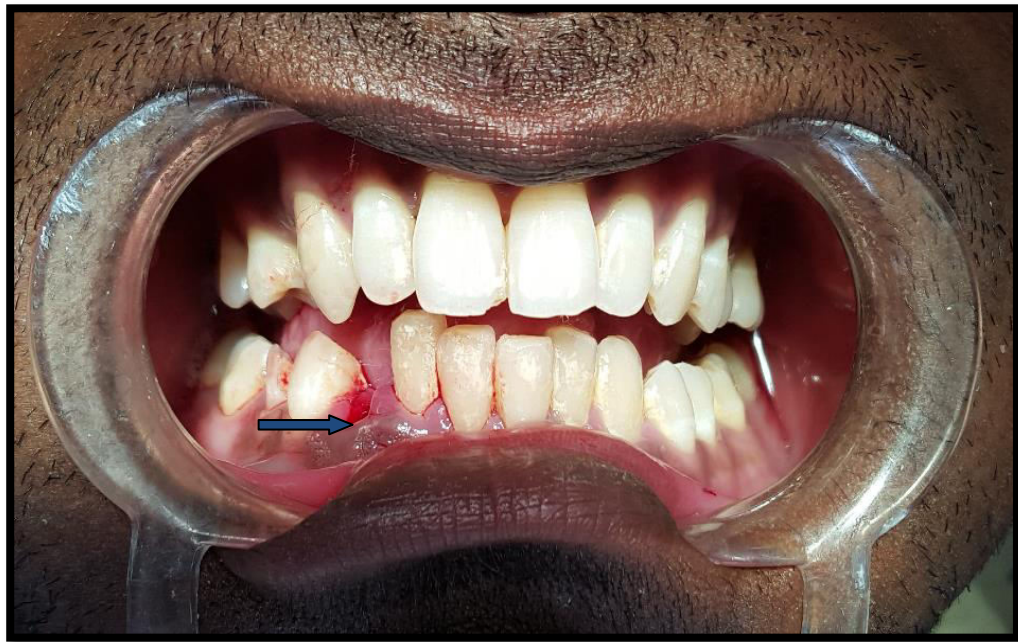1a. Bleeding line was noticed in the cervical region (arrow) of mandibular right canine



1b. Periapical radiograph of the transverse complicated crown-root fracture



1c. Intraoral view after removal of crown portion of mandibular right lateral incisor



**Figure 2:**

Figure 2a. Periapical radiograph of the definitive root canal treatment.

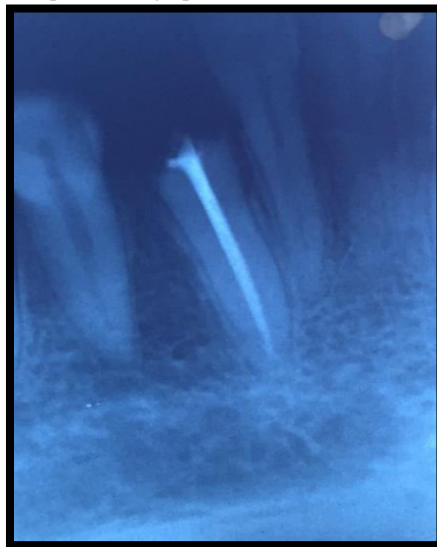


Figure 2b. Laser assisted gingivectomy

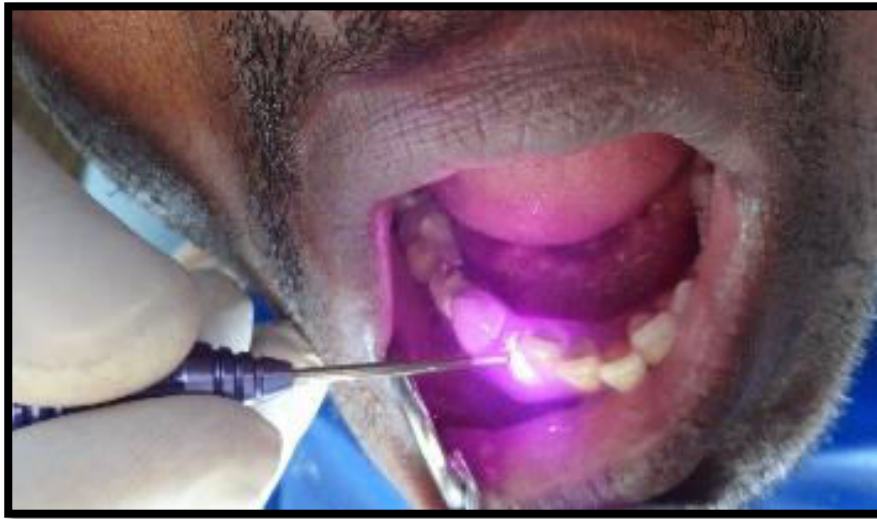

Figure 2c. Intra oral view of placement of prefabricated fiber post followed by a composite core build up

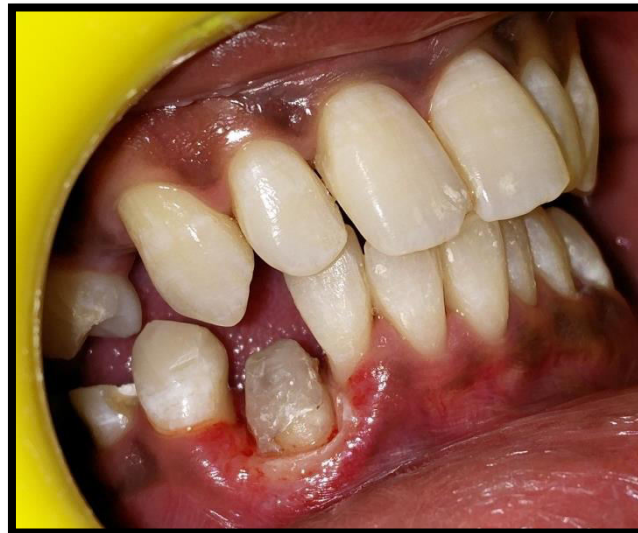

Figure 3

Figure 3a. Apically positioned flap (APF) with osseous reduction.

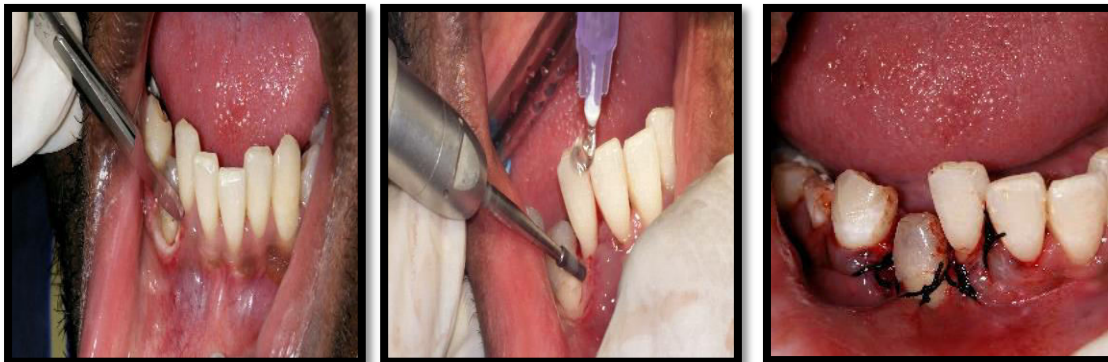


Figure 3b. After 1 week of APF surgery

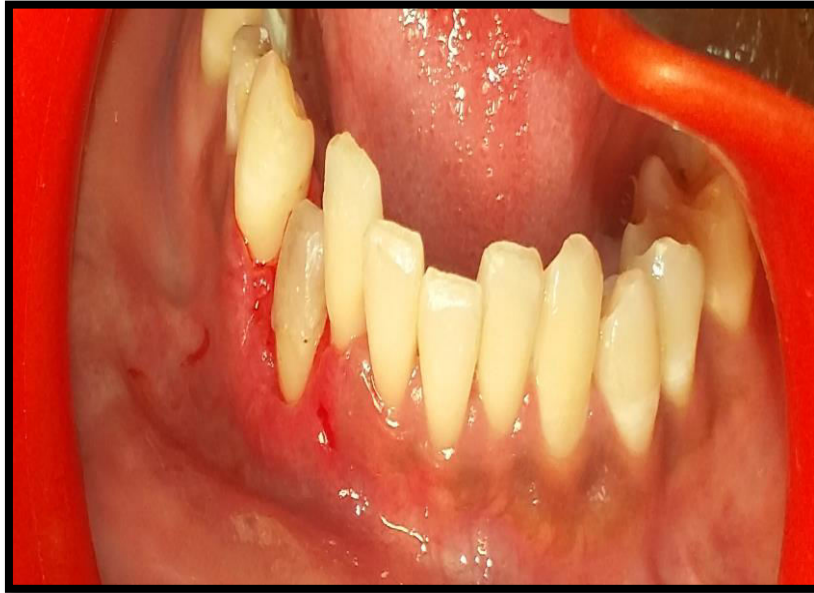

Figure 4:

Figure 4a. Intra oral and periapical radiograph view of the final restoration.

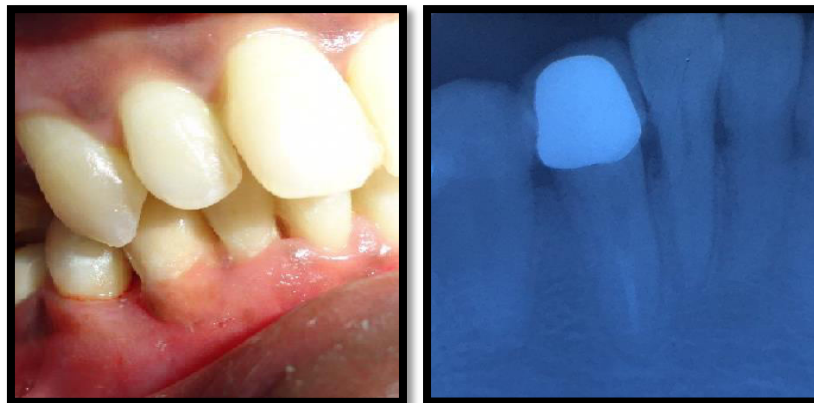


Figure 4b. Intraoral and periapical radiograph view of the patient 24 weeks after the treatment.

